

### Heel Pressure Ulcer

#### PATIENT INFORMATION:

91-year old female

#### WOUND HISTORY:

Pressure ulcer on the left posterior heel. Wound had been present for 9 months. Previous treatments included a cellular tissue product, a silver dressing, and a heel lift boot.

#### DIMENSIONS:

Prior to SNAP™ Therapy, the wound measured 9mm x 7mm with a depth of 5mm.

#### COMORBIDITIES:

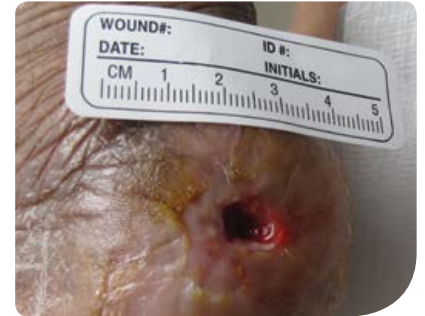Hypertension and peripheral artery disease.

#### SNAP™ THERAPY TREATMENT:

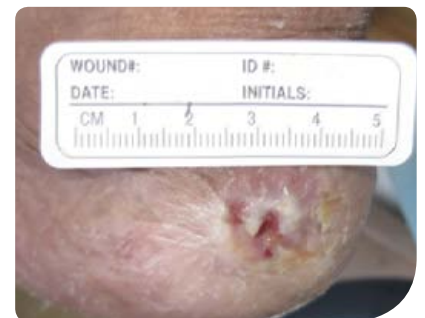
Treated with SNAP™ Therapy for 9 days for a total of three dressing applications with an average application time of 6.3 minutes.

#### OUTCOME:

Complete epithelialization and closure achieved one week after SNAP™ Therapy discontinued.



Start of SNAP™ Therapy



Day 9

**SMART** FOR CLINICIANS

**SMART** FOR PATIENTS

**SMART** FOR FACILITIES